

## HEREDITARY SPASTIC PARAPLEGIA IN A FILIPINO FAMILY: A CASE REPORT

**P. Ruth Siongco**, Raymond Rosales

*Neurology and Psychiatry, University of Santo Tomas Hospital, Philippines*

[paulasiongco@gmail.com](mailto:paulasiongco@gmail.com)

This is a case of a 50 year-old, male, from Bulacan, Philippines, who consulted due to difficulty in ambulation.

His symptoms started with numbness of his left lower extremity that was aggravated by prolonged standing and relieved by rest. In 2012, he had lumbosacral pain and difficulty sitting and standing requiring assistance. He had difficulty in articulation and dysphagia. His weakness progressed involving his right lower extremity. He was hesitant to initiate a step, ambulated more slowly, had smaller steps, and a slightly wide-based gait. On ambulation, he had difficulty flexing his thigh muscle. He had a reduced sense of balance and a tendency to fall. There were no bowel and bladder disturbances. He consulted a neurosurgeon, where a series of neuroimaging studies of the spine revealed normal results.

On examination, his cognitive function was intact with no memory disturbances. Visual acuity: 20/50 for both eyes, there was sensorineural hearing loss on his left ear, moderate dysarthria on pharyngeal sounds. He had normal muscle bulk, with spasticity on all extremities more profound on the left. He had left-sided hemiparesis, dysdiadochokinesia on both left extremities. Romberg's sign positive. He had a crouch gait, wide-based stance, decreased cadence, and shortened step length. He had difficulty initiating a step and flexing his thighs. He was hyperreflexive on all extremities with Babinski and ankle clonus, bilateral.

*\*\*Blood samples of the family were sent for genetic workup.*

### HSP FAMILY GENOGRAM

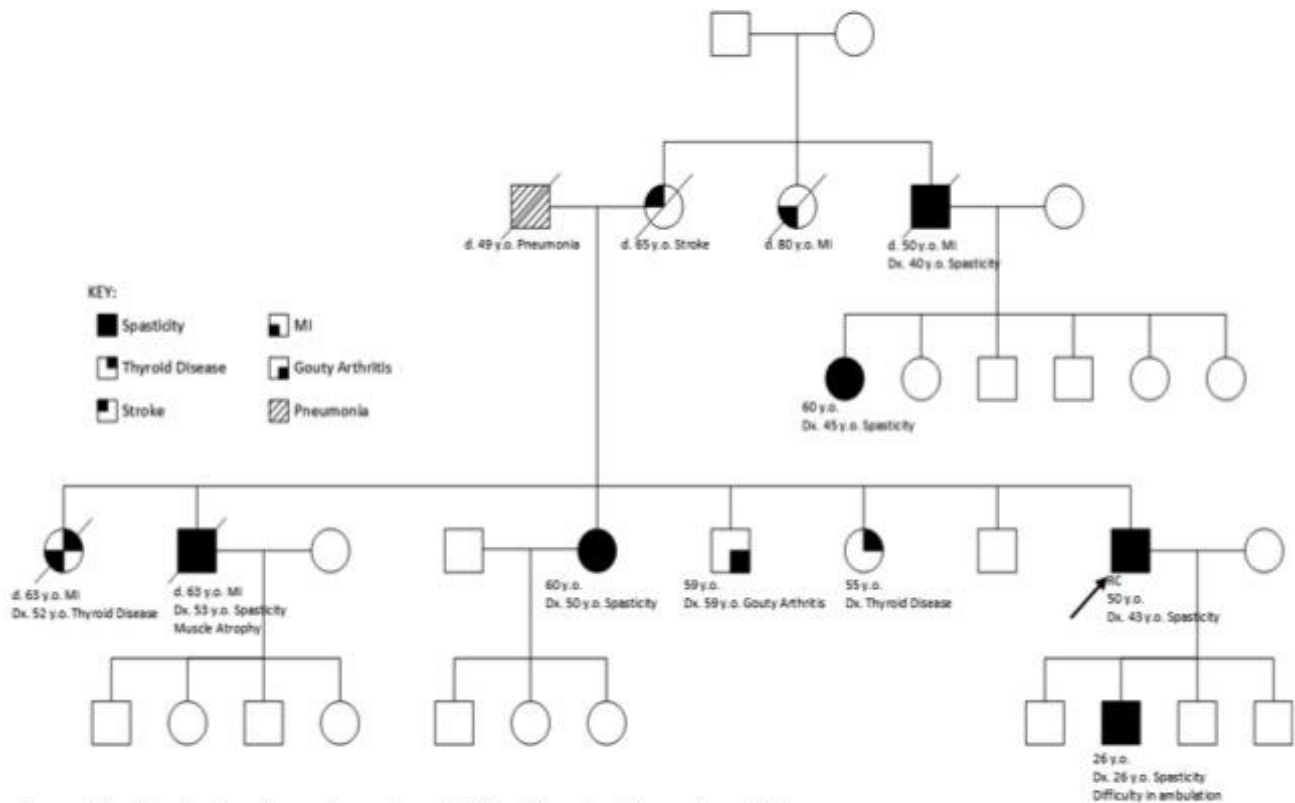


Figure 1. Family showing signs and symptoms of difficulty in ambulation and spasticity.